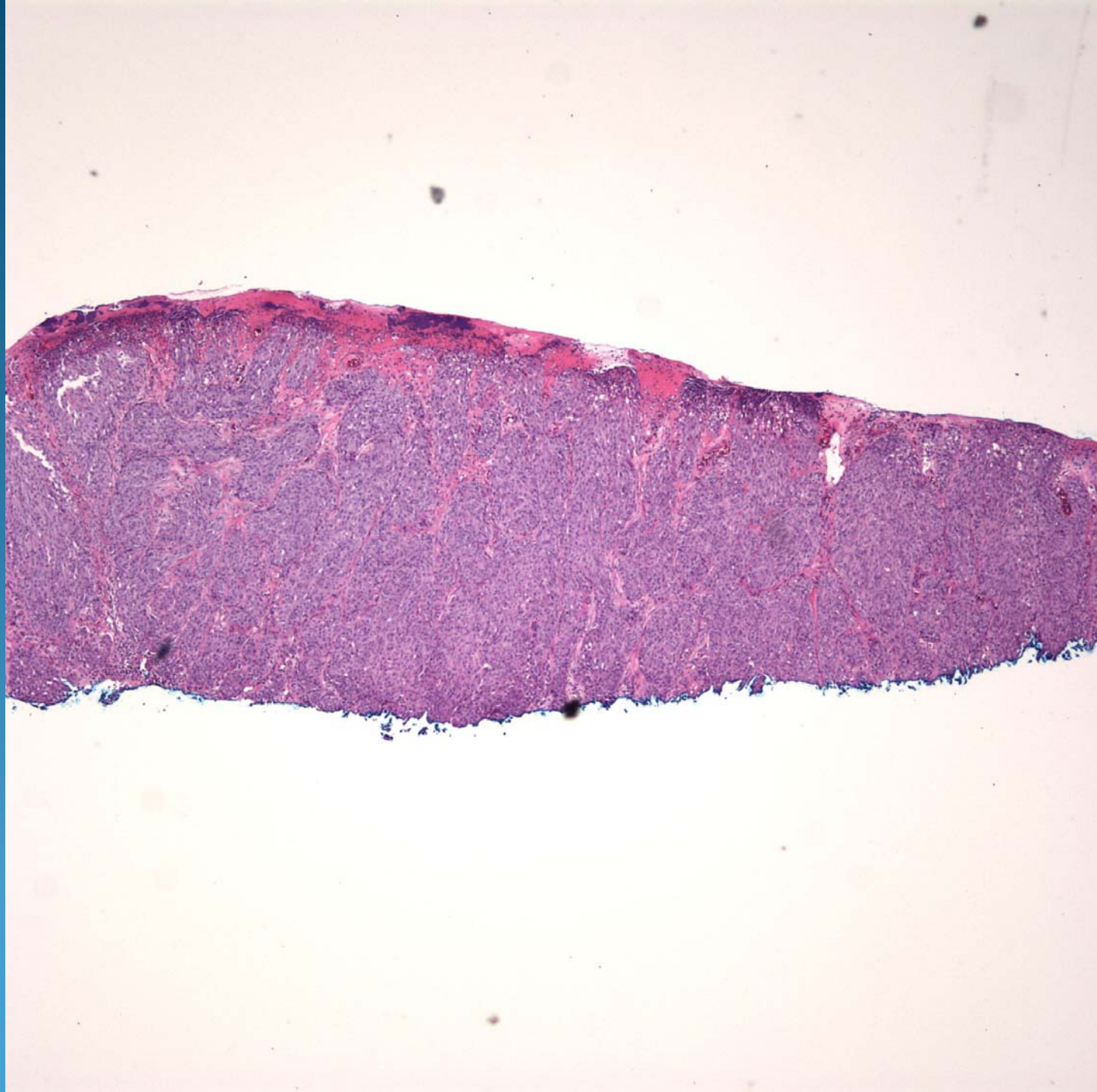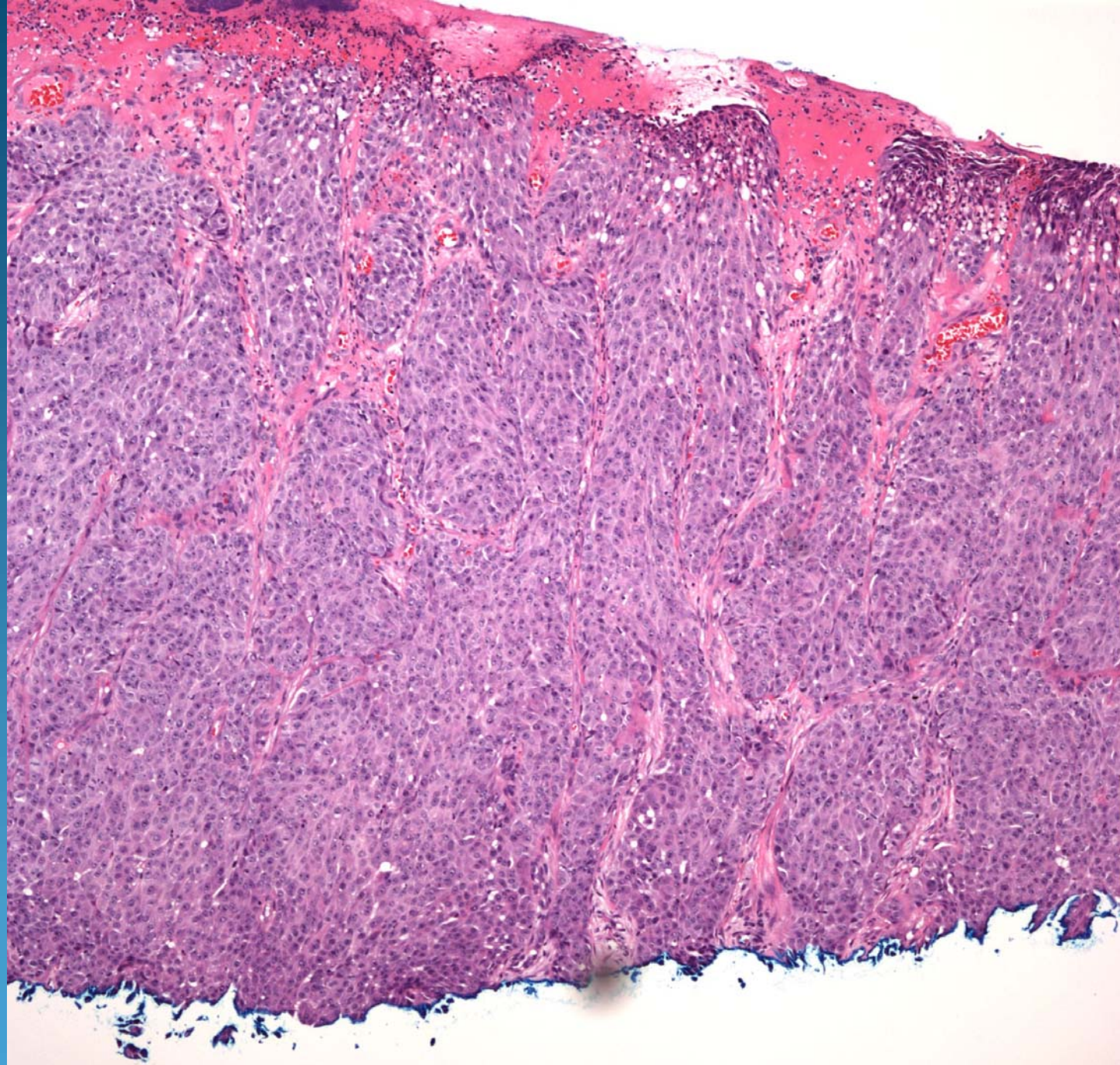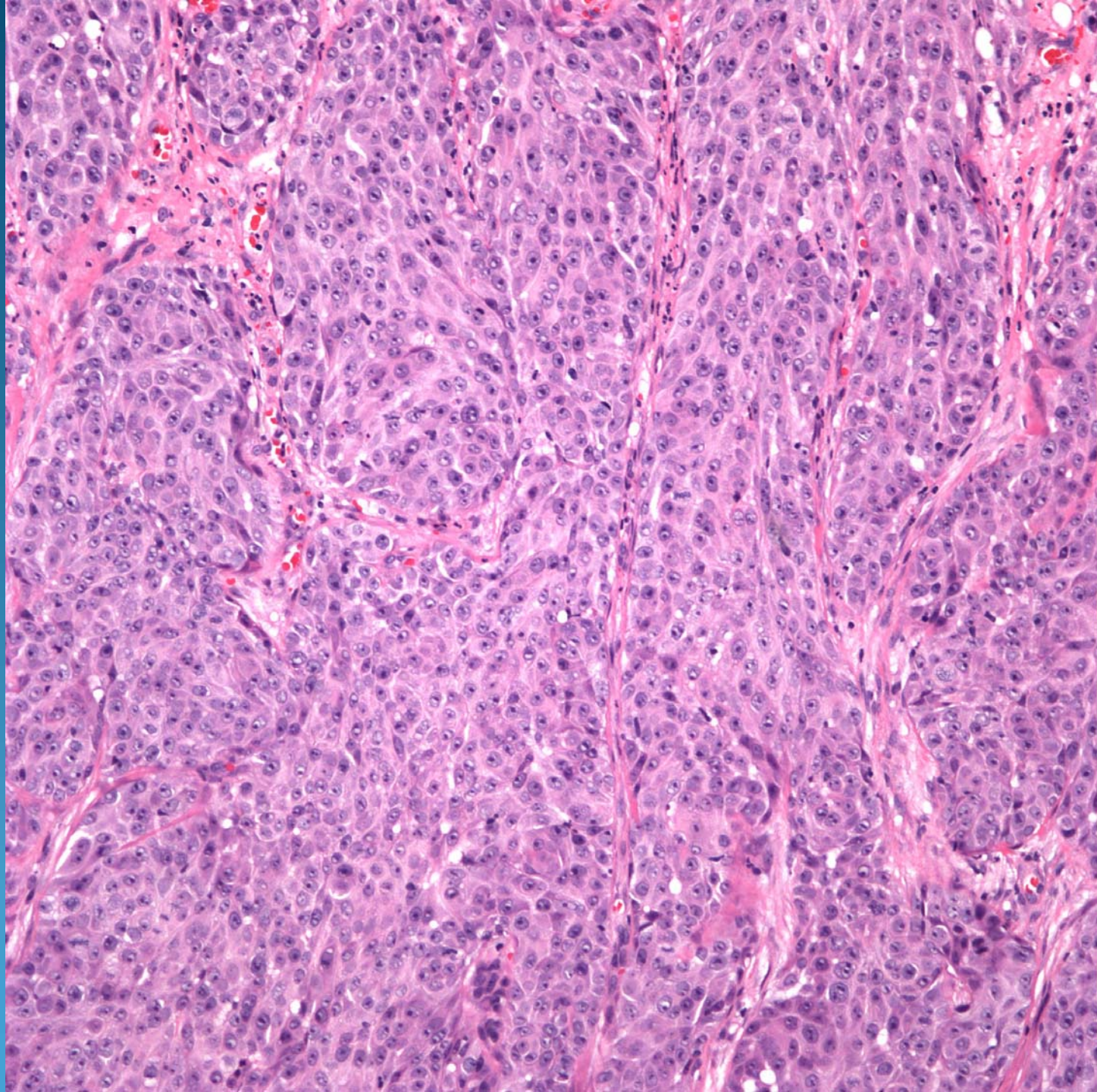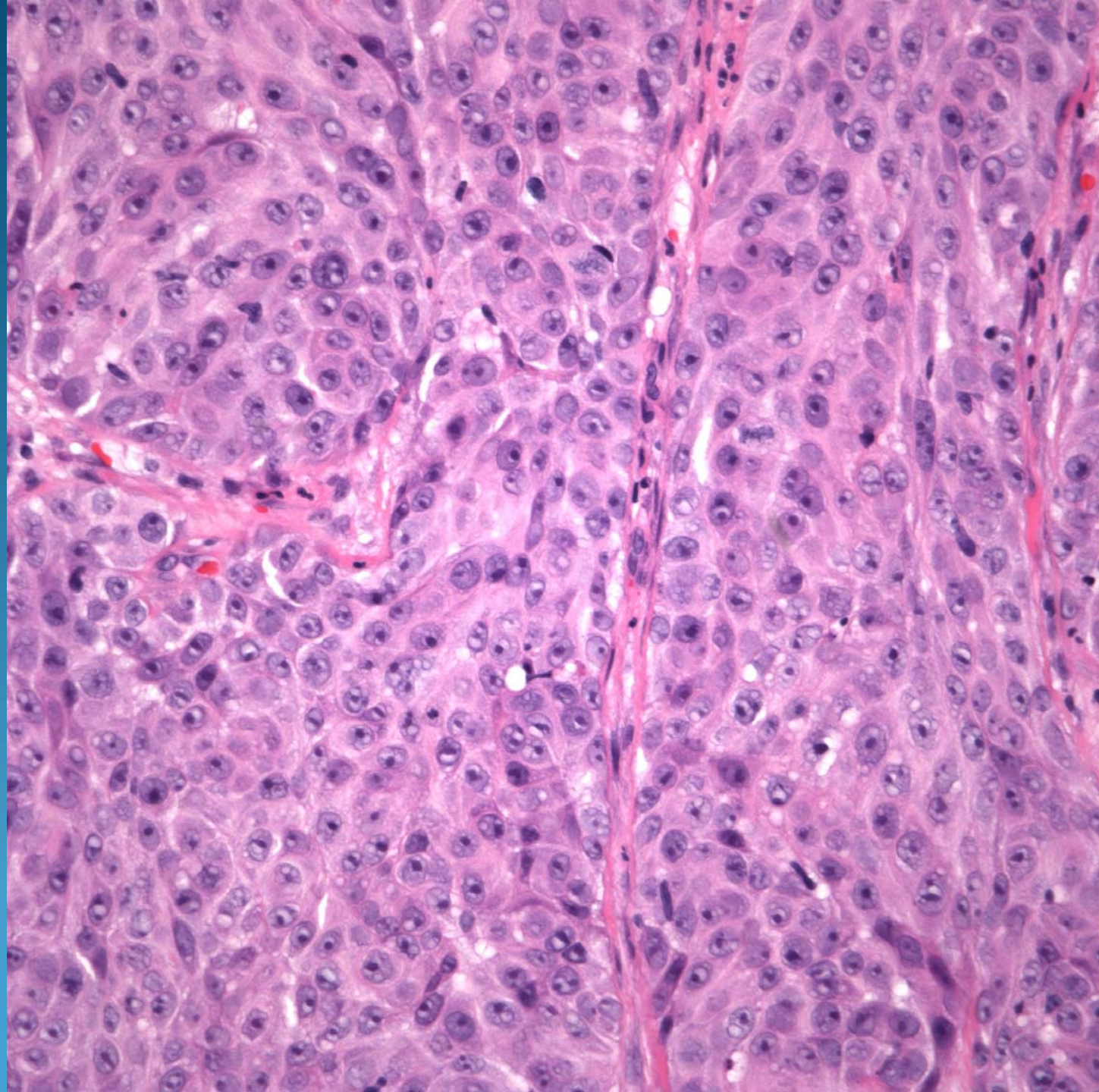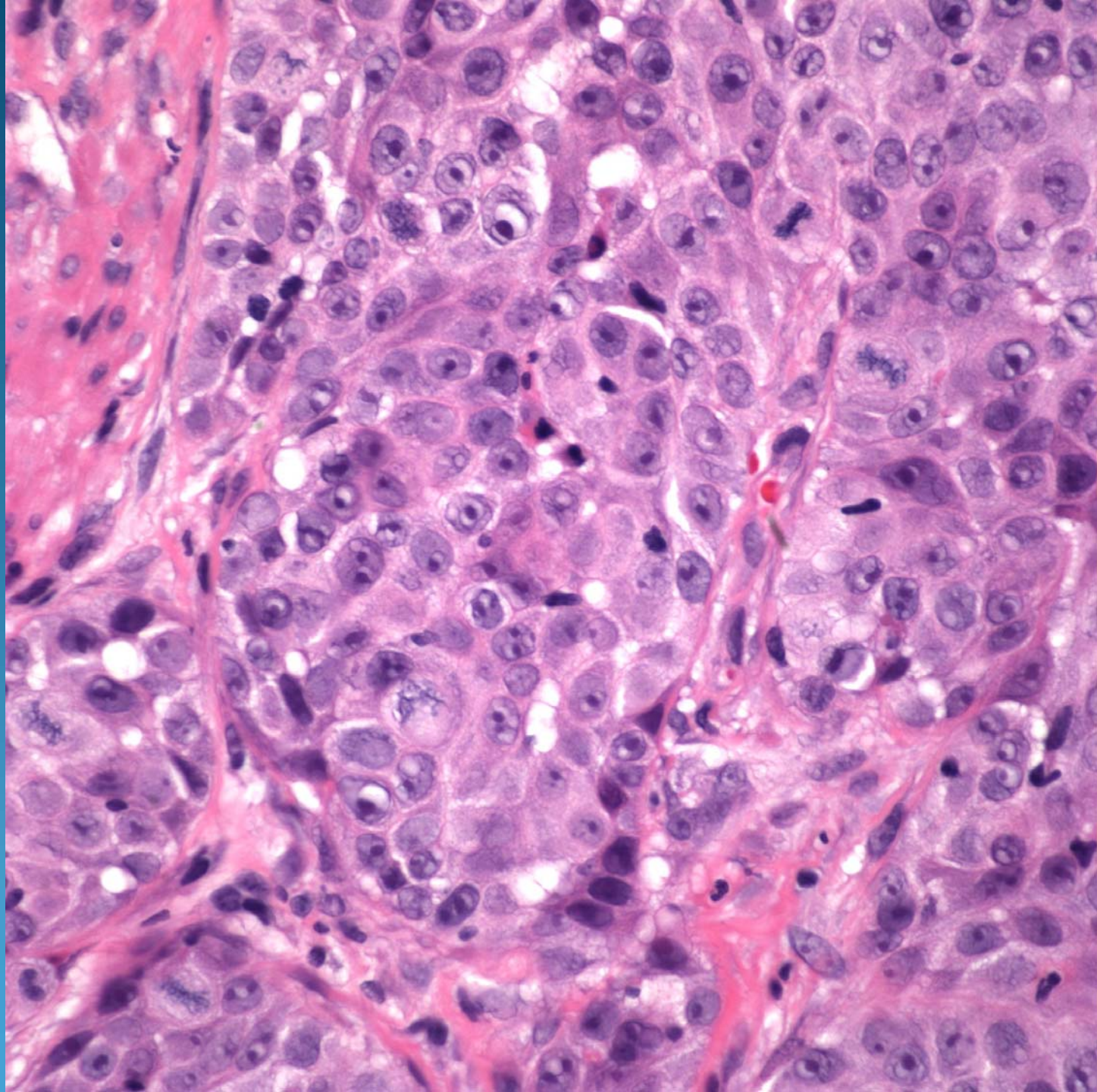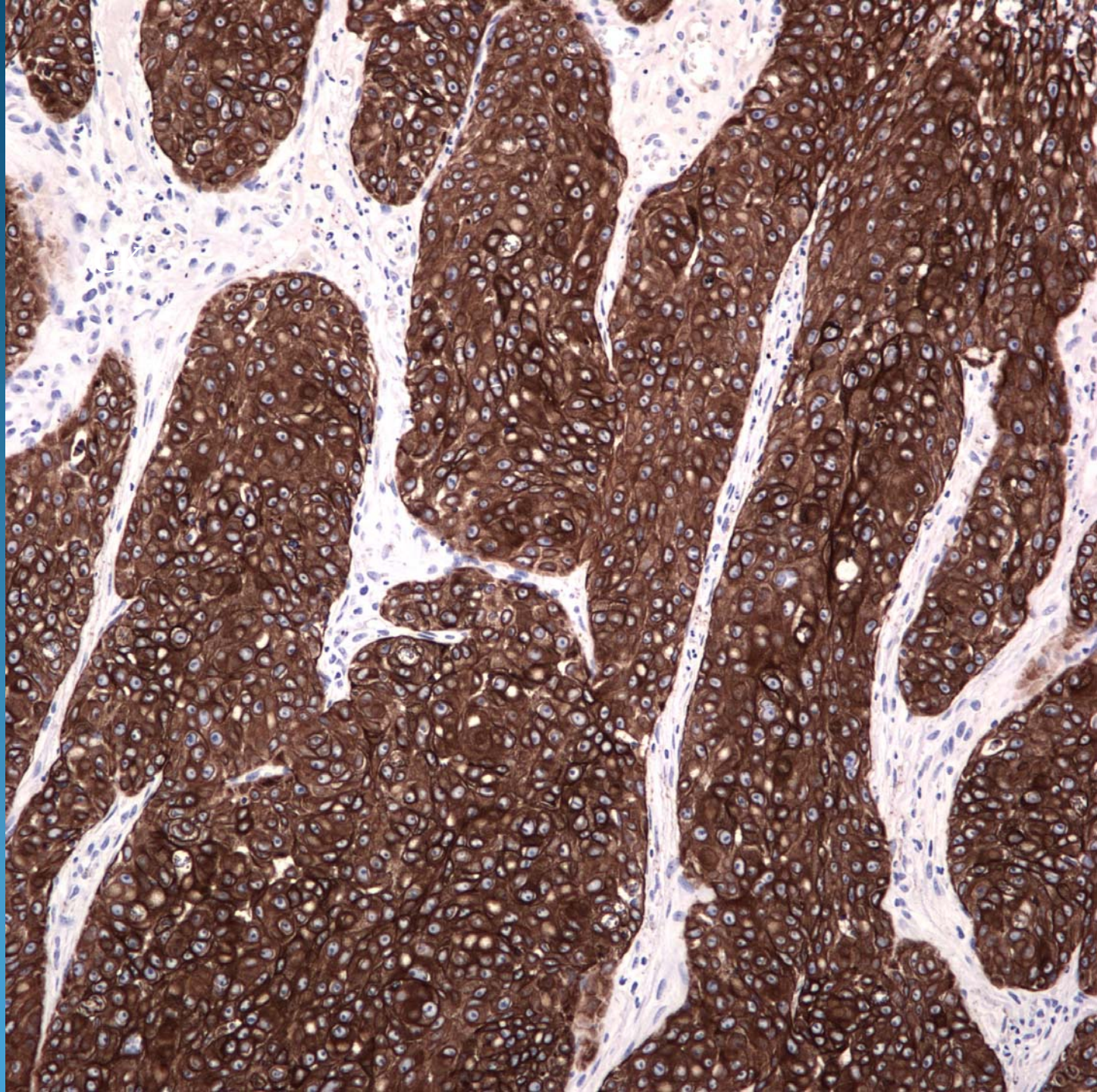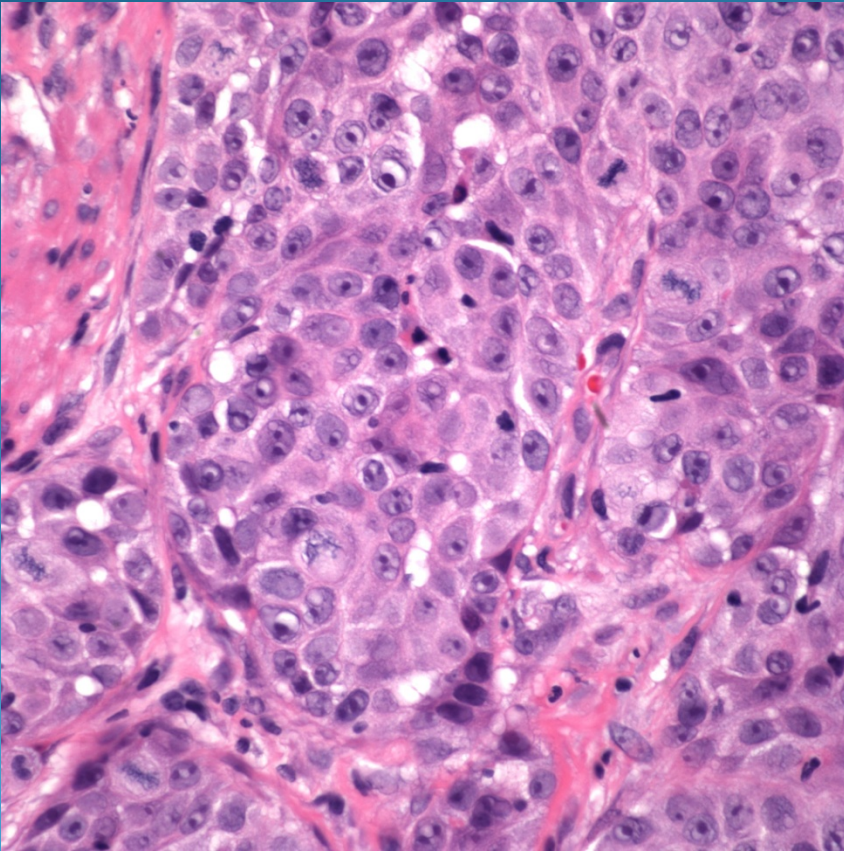


# Invasive Squamous Cell Carcinoma, Poorly Differentiated



# Pearls



- Poorly differentiated epithelial cells with minimal keratinization
- May show focal intercellular bridges
- Acantholytic changes may mimic angiosarcoma
- May need IHC to confirm (CK+, CD31-)